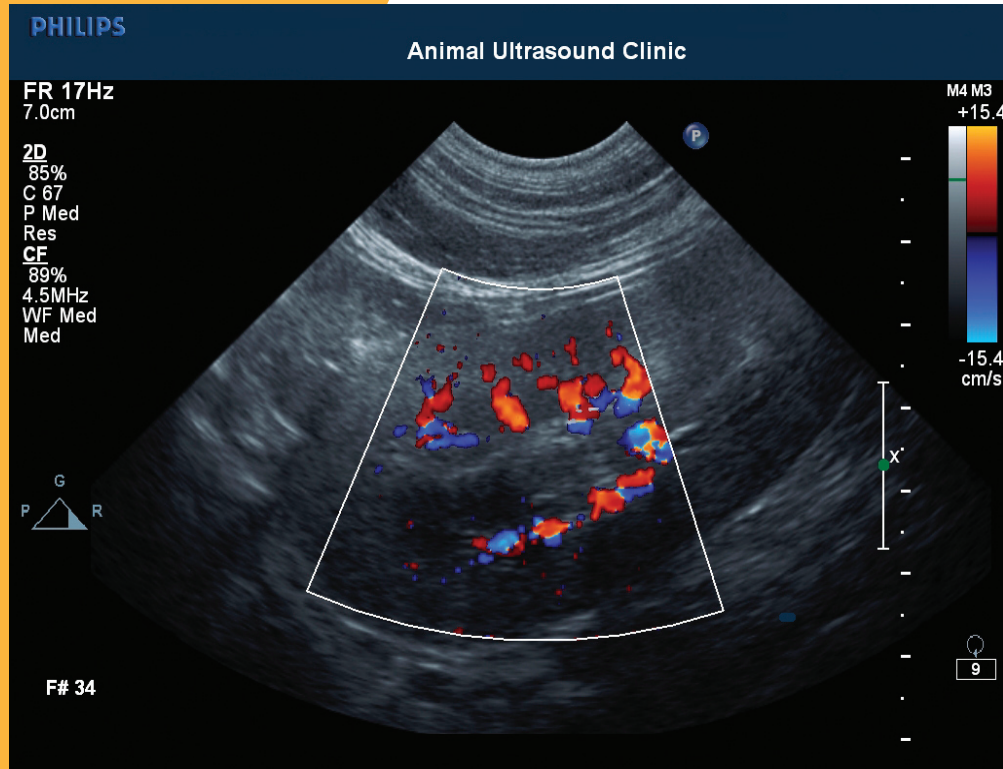
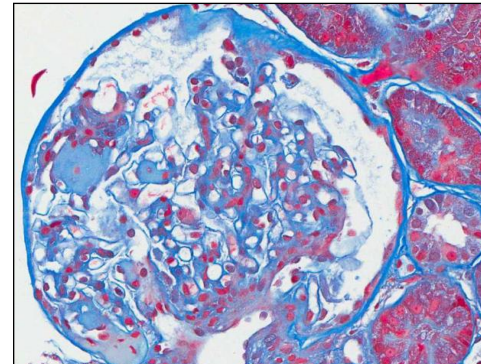
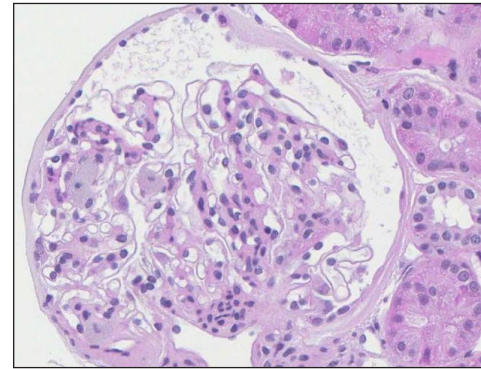


# Have you seen: Canine Glomerulonephropathy?



THE ANIMAL ULTRASOUND CLINIC 131 Boston Street, Salem, MA



Renal biopsy may be performed with the use of color flow Doppler to help place the biopsy needle on a path that will avoid the arcuate arteries. The needle path chosen for this case was tangential to cortex of the cranial pole of left kidney.

The H&E and Masson's trichrome stains of the single glomerulus depicted in these panels show atrophy and small to large foci of mesangial expansion by extracellular matrix material. EM shows amyloidosis is present. Pathology is by the TAMU Renal Pathology Service.

*Understand more clearly.  
Treat more precisely.*

Dr. Tom Rossi, Internal Medicine; Dr. Neil Harpster, Cardiology

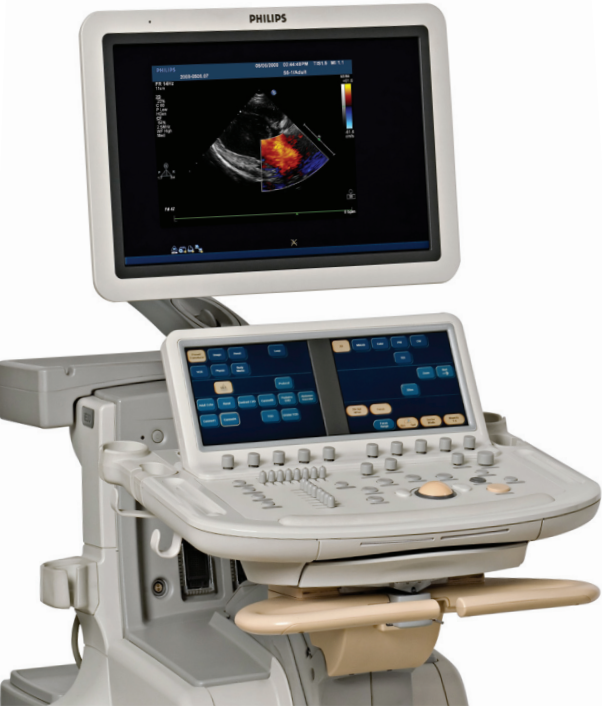

## THE ANIMAL ULTRASOUND CLINIC

131 Boston Street  
Salem, MA 01970

T: 978-740-9800  
F: 978-740-9945

[www.animalultrasound.com](http://www.animalultrasound.com)



### Salem Clinic Schedule October 2010

SUN	MON	TUE	WED	THU	FRI	SAT
					1	2
3	4	5	6	7	8	9
10	11	12	13	14	15	16
17	18	19	20	21	22	23
24	25	26	27	28	29	30

■ Indicates open by appointment.  
Hours: 8-4 Mon, Tue, Thu, Fri; 2-4 Wed, Sat

### Did You Know?

We are hosting a Non Sibi day on Nov. 6th at the Salem Clinic to assist those clients who, for financial reasons, would otherwise be unable to have their pet scanned. Scans are \$95.00 on this day. Please call for info and to schedule your patient.

© 2010 THE ANIMAL ULTRASOUND CLINIC

PRST STD  
US POSTAGE  
PAID  
SALEM, MA  
PERMIT NO. 36